



Examining the Science of Image Processing and its Application in Medicine (Dentistry)

Seyed Ahmadreza Ahmadi¹, Rambod Kheirkhah Deilamian², Sepehr Eslami Pirharati³, Amirhossein Akbarpour⁴, Mohammadreza Karimi^{5*}

¹Department of Biomedical engineering, Sahand University of Technology, Tabriz, Iran
Ahmadi.ah.1998@gmail.com

²Student Research Committee of Dental School, Qazvin University of Medical Sciences, Qazvin, Iran
Ramikh15@gmail.com

³DDS, General Dentist, Qazvin, Iran
Sepehreslami76@gmail.com

⁴Biomedical Engineer, Shiraz, Iran
amirhakp@gmail.com

⁵Oral and Dental Disease Research Center, School of Dentistry, Shiraz University of Medical Sciences, Shiraz, Iran
Karimi.mr.dds@gmail.com

Abstract

In recent years, we have witnessed the expansion of artificial intelligence research and its applications in various aspects of human life. One of the key subfields of this domain is image processing, which attracts numerous researchers worldwide annually. Image processing is widely utilized in medical research to enable precise and effective treatments for diseases, for instance, through algorithms powered by artificial intelligence. The integration of AI and deep learning has significantly advanced recent studies and their application in medical imaging, particularly in using radiology images to diagnose various diseases. Researchers have achieved remarkable progress in the early detection of certain illnesses using these methods. Numerous studies in the field of image processing have been conducted, finding applications in diverse areas such as medicine, robotics, military, and meteorology. Medical images, including X-rays, CT scans, MRIs, and other types, are among the most essential diagnostic tools for physicians and have consistently been the focus of extensive research.

One of the most significant applications of image processing is in dentistry, where substantial research has been conducted. Today, automated analysis of oral, jaw, and facial images is considered one of the most valuable methods for disease diagnosis, treatment planning, and monitoring the treatment process. This article provides a brief review of the role and importance of image processing techniques in dentistry. Some of the most impactful applications of dental image processing include the early detection of tooth decay, personal identification, and determining the degree of tooth whitening. This article introduces, analyzes, and evaluates these applications.

Keywords: Medicine, Image Processing, Dentistry



1. Introduction

Medical imaging is one of the most critical tools for diagnosing, predicting, and treating medical diseases and disorders. The precision and speed of medical imaging play a crucial role in early disease detection, monitoring clinical changes, and tracking treatment outcomes. This field captures graphical and visual data from inside the human or animal body in digital form to provide valuable information for diagnosis, treatment, and prevention of diseases.

In the past, many individuals lost their lives due to the lack of advanced medical technologies. However, with modern advancements, the process of diagnosing numerous diseases has significantly improved. The development of image processing technologies and artificial intelligence has made medical image processing one of the most vital research areas in medical sciences (Ardebili & Ghasabi, 2024). Oral and dental diseases can seriously impact health, making their diagnosis and treatment highly significant. Recently, image processing and AI methods have emerged as effective and efficient solutions in this field.

An example of image processing in dentistry is the detection and imaging of oral and dental diseases. For instance, X-ray image processing can identify weaknesses and defects in the dental system. Other imaging techniques include magnetic resonance imaging (MRI) and optical imaging. Additionally, AI techniques like deep learning (DL) and neural networks have proven effective in detecting cracks, fractures, root infections, gum diseases, and tumors. Despite these advancements, AI serves as an auxiliary tool and cannot entirely replace the expertise of specialists and dentists (Mahmoudi et al., 2024).

Modern advancements now allow us to achieve valuable and essential findings using digital imaging. One key application of image processing is in the medical field, which, due to its direct connection to human health, involves particular sensitivities and complexities (<http://elecpro.ir>).

Dentistry is no exception. Various imaging methods such as radiography techniques, visible light, laser light, and electrical current (ECM) are employed for dental imaging. Among these, radiography techniques are favored for their non-invasive nature, ability to examine the 3D structure of teeth, capability to analyze decay and damage to different dental anatomy structures, and accessibility compared to some other methods (<http://drbassirradiology.ir>).

The automated study and processing of these images pursue three main goals: processing, analyzing, and understanding the image. Therefore, automated computer-based processing systems perform these tasks with greater speed and accuracy. The process involves stages like preprocessing, image enhancement, image transformation, classification, and analysis (<http://www.iranianbme.com>).



The article is structured as follows:

Section 2: General concepts of dentistry, dental anatomy, and imaging techniques.

Section 3: Methods for identifying dental caries.

Section 4: Person identification based on dental images.

Section 5: Determining the level of tooth whitening.

Conclusion: Summarizes the article's findings.

2. Research Background

Armaghan Hodehshenas et al. (2024) conducted a study titled A Comprehensive Method for Enhancing the Accuracy and Precision of Brain Tumor Diagnosis Using Image Processing and Machine Learning Techniques. This study introduced an efficient method for diagnosing brain tumors from MRI images by combining machine learning and image processing techniques.

Given the significant impact of brain tumors on individuals' quality of life, early detection is essential. Due to the high similarity between tumor tissues and other brain tissues, precise methods are required. This approach included four main steps:

1. Noise removal in the preprocessing phase,
2. Using the watershed algorithm for segmentation,
3. Extracting key features with the GLCM algorithm,
4. Enhancing classification accuracy with a perceptron neural network.

The method was implemented in Python and evaluated on the BRATS dataset, achieving 93% accuracy and 91% precision in tumor detection (Armaghan Hodehshenas et al., 2024).

Zareh Ekbatani and Shiri Ahmadabadi (2024) conducted a study titled A Combined Method for Improving Brain Tumor Classification and Detection, examining strategies to enhance accuracy in identifying tumor lesions in brain tissue. This research utilized three combined methods, including clustering, optimized clustering, and thresholding approaches. The dataset comprised 253 brain images, downloaded from reputable databases, including 98 non-tumorous and 155 tumorous images. Eleven images were selected for analysis, and after preprocessing operations, the proposed methods were applied to evaluate their efficiency.

The results indicated that the thresholding algorithm achieved the highest performance with an average accuracy of 84.8663%, followed by FCM clustering and basic clustering algorithms with average accuracies of 80.8627% and 79.1651%, respectively. Ultimately, the proposed combined method achieved an overall accuracy of 63.94% after simulation,



which was considered acceptable in this field. Other evaluation criteria also highlighted the satisfactory performance of the proposed method (Zareh Ekbatani and Shiri Ahmadabadi, 2024).

Azizi and Abbasi Nishabouri (2024) also conducted a study titled Investigating the Application of Deep Convolutional Neural Networks in Processing COVID-19 CT Images and Disease Diagnosis. This study analyzed the use of convolutional neural networks (CNN) in processing COVID-19-related CT images. It emphasized the application of deep learning models for feature extraction and optimization from CT images.

The COVID-19 detection system in this study was designed using CNN models and open-source software such as Visual Studio, Kaggle, Google Colab, Keras, and Python. The results demonstrated that deep convolutional networks provide significantly high accuracy in image processing. Moreover, with proper layer structuring, a considerable improvement in COVID-19 diagnosis based on CT images can be achieved (Azizi and Abbasi Nishabouri, 2024).

1. Application of Image Processing in Medicine (Tumor Detection) – Raisi, 2023

In 2023, Raisi conducted a study titled Application of Image Processing in Medicine (Tumor Detection using MATLAB). This article clearly explains the programming steps in MATLAB based on a new tumorology theory. Additionally, it examines various methods for automatic brain tumor detection, histograms, the proposed method, and simulation results (Raisi, 2023).

2. Diagnosis of COVID-19 Using Chest CT Scan Image Processing Techniques – Safdarian and Jafarnia Dabanlou, 2021

In 2021, Safdarian and Jafarnia Dabanlou carried out a study titled Diagnosis of COVID-19 Using Chest CT Scan Image Processing Techniques. The aim of this research was to develop a precise diagnostic method for the intelligent and automated identification of COVID-19 through chest CT scan image processing techniques and to propose the results as a precise diagnostic tool to complement CT scan devices.

Methodology: Digital image processing algorithms, such as segmentation and feature extraction from images, were used, along with various statistical analysis methods applied to the extracted features. The study analyzed COVID-19 diagnosis (data from 79 individuals) using CT scan images of male and female participants of different ages, evaluating the effects of the disease on the lungs of the affected individuals. The research was conducted in spring 2020 at the Faculty of Medical Sciences and Technologies, Science and Research Branch, Tehran.

Findings: This intelligent method, based on feature extraction from lung CT scan images, demonstrated high accuracy in diagnosing the disease across different categories (gender



and type of damage caused by the disease). It was observed that most patients experienced more tissue damage in the lower sections of both lungs than in the middle and upper lobes.

Conclusion: The algorithm proposed in this study could accurately distinguish CT scan images of healthy individuals from those of COVID-19 patients (Safdarian and Jafarnia Dabanlou, 2021).

3. Diagnosis of Heart Disease Using PCA and Neural Networks – Shahram Shams Elkatabi et al., 2017

In 2017, Shahram Shams Elkatabi and colleagues conducted a study titled Diagnosis of Heart Disease Using PCA and Neural Networks. The research employed Principal Component Analysis (PCA) and Learning Vector Quantization (LVQ) neural networks to analyze the relevant data. The dataset used in the study was sourced from the School of Medicine at Cleveland State University, USA (Shahram Shams Elkatabi et al., 2017).

4. Diagnosis of Leukemia Using Optimization Algorithms and Neural Networks – Goudarzi and Bagheri, 2017

In 2017, Goudarzi and Bagheri explored Diagnosis of Leukemia Using Optimization Algorithms and Neural Networks. Samples from 50 leukemia patients (acute lymphoblastic leukemia) were prepared, and required images were captured from all cells using prepared slides in the laboratory. These images were used as essential patterns for training artificial neural networks. Various neural networks, including RBF, BP, MLP, PNN, and GRNN, were utilized. Additionally, an unsupervised clustering method, KNN, was examined for comparison with other methods.

Results: The software developed in this study was capable of distinguishing white blood cells, identifying normal and abnormal cells, and further differentiating between subtypes L1, L2, and L3 (Goudarzi and Bagheri, 2017).

General Concepts

The use of computers in all dental procedures represents the first and most widely accepted clinical aspect of dentistry. Numerous technologies have been introduced in this field to provide better, faster, more precise, and more convenient care and treatment for patients. This section discusses the fundamental and specialized concepts related to dentistry, including the anatomy of teeth, dental injuries, and radiographic imaging techniques.

2-1. Tooth Structure

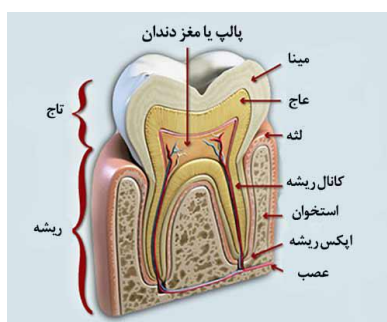Each tooth consists of a crown and a root. The four main tissues that make up a tooth are enamel, cementum, dentin, and pulp. The first three are classified as hard tissues, while the last is considered soft tissue. The crown is covered by enamel, and the root by cementum (Stanley, 2015).

As shown in Figure 1, the crown is located outside the gums, while the root is embedded within the jawbone (Tebyan). Enamel acts as a protective layer for the dentin in the tooth's



crown. Cementum, a bone-like tissue without blood vessels, covers the external surface of the dentin in the root area. Dentin constitutes the main volume of the tooth and is considered a living tissue (Dr. Hashemi's Dentistry) surrounding the tooth pulp (Tebyan).

The pulp tissue supplies blood, vessels, and nerves to the tooth and occupies the internal cavity of the tooth (Stanley, 2015).



"Figure 1. Structure"

Tooth (<http://www.drhashemi.ir/dentistry/17-teeth.html>)

2-2. Dental Injuries

In this section, we provide a brief overview of common dental injuries.

2-2-1. Dental Plaque

Dental plaque refers to a soft, gel-like layer that adheres to the surface of the teeth and is a living substance with a layered structure (Yasini et al., 2016). This sticky, soft, transparent, and firmly adhered material accumulates on the tooth surface and is commonly referred to as plaque (Roberson et al., 2008). Plaques are composed of a large amount of bacteria, their products, and water, and their accumulation on the surface of the teeth follows a very organized process (Yasini et al., 2016). Plaques metabolize available carbohydrates for energy and produce organic acids. These acids can then lead to the formation of decay lesions by dissolving the crystal structures of the tooth (Roberson et al., 2008). In fact, the gelatinous nature of the plaque allows the acid to remain on the tooth surface for a long time, leading to demineralization and the formation of cavities. Since saliva does not reach the underlying layers, this prolonged acidic condition results in further tooth damage (Mousavi Nasab & Ashrafi Jo, 2004). If plaque remains on the teeth for more than a few days, it gradually becomes hard and solid (<http://daneshnameh.roshd.ir/mavara/mavara-index.php>).

2-2-2. Tooth Decay

Tooth decay is an infectious microbial disease that causes the dissolution and destruction of the tooth's calcified tissue. The process of decay begins with the loss of minerals and the



breakdown of tooth tissues, which varies in speed and predictability among individuals. Decay lesions typically occur due to the accumulation of bacteria capable of creating an acidic environment sufficient to remove the minerals from the tooth tissue (Roberson et al., 2008). This disease, by destroying the tooth structure, can cause pain, tooth loss, infection, and in severe cases, lead to death. The greatest damage to teeth occurs due to the presence of carbohydrate materials such as sucrose, fructose, and glucose (Strassler, 2002). Decay can be identified in three different areas of the tooth: pit and fissure decay, smooth surface decay, and root decay. Pit and fissure decay (occlusal decay) is the most common type of decay and is usually detected through visual examination, provided there is adequate light and the tooth is dry and clean (Hilton et al., 2014). In addition, there are various clinical methods for diagnosing this type of decay, with the most common being patient interviews, diagnostic tools, dental explorers, and radiographic examinations (Kudosari et al., 2013).

2-2-3. Tooth Decalcification Decalcification is a process in which calcium is lost from the teeth. This process causes white spots to appear on the surface of the teeth. If proper oral hygiene is maintained promptly, decalcification can be reversed. However, if proper dental care is not followed, it may lead to tooth decay (<http://www.wisegeek.org/what-is-tooth-decalcification.html>). Decalcification is considered the stage before tooth decay when the acid has not yet reached the inner layers of the tooth, but it has weakened the outer layer (<http://www.winghavenortho.com/decalcification.php>). When teeth are not properly cared for, plaque forms on the surface of the teeth, and bacteria in the plaque produce acid that damages the enamel and removes the calcium that strengthens the teeth (Hilton et al., 2014). Fluoride treatment is often recommended to combat tooth decalcification. It is also advised that, along with brushing and flossing, regular visits to the dentist every six months or annually should be maintained (<http://www.wisegeek.org/what-is-tooth-decalcification.html>).

2-3. Dental Radiography

Radiography is a medical imaging method in which X-rays produced by an X-ray machine pass through the body tissues of a patient and hit a digital receptor or film, forming a radiographic image (White & Farrow, 2014). Using X-rays, a two-dimensional image of an object is created on a sensitive surface like a film, resulting in dark and light spots. Factors such as reduced exposure time, smaller storage volume, and time and cost savings make digital radiology the best alternative to traditional film-based radiography (Amirkhosrow & Jafari, 2008). Radiographic images assist greatly in diagnosing dental abscesses, bone damage, jaw fractures, and jaw and dental abnormalities (<http://www.dandane.ir>), and they serve as a valuable complement to a full clinical dental examination for diagnosing tooth decay. Decay lesions appear as a radiolucent (darker) area (White & Farrow, 2014). Based on the direction of the image and the extent of the coverage of the tooth, bone, and surrounding soft tissues, radiographs are classified into intraoral and extraoral categories. Intraoral radiographs are used in detecting decay and include several types: panoramic, bitewing, and periapical. Panoramic images show the entire jaws, teeth, sinuses, nasal areas, and temporomandibular joints and are used for general dental examinations, detecting impacted teeth, and diagnosing tumors and cysts. Bitewing images show the crowns and



parts of the roots of the teeth in both jaws, along with details of the upper and lower parts of one side of the teeth (Taghavi et al., 2014). Bitewing is a reliable method for diagnosing occlusal decay (Hilton et al., 2014). Periapical radiographs show the left side of the tooth, capturing one tooth or a maximum of three teeth in full. This type of radiograph shows the full height of each tooth, from crown to root, and the base connected to the jaw, mainly used for studying the tooth's root (Taghavi et al., 2014). These techniques can provide useful diagnostic information to complete clinical examinations. It is recommended that radiography be prescribed only when it can aid in more accurate diagnosis (White & Farrow, 2014).

3. Methods of Detecting Tooth Decay Early detection and prevention of dental issues, or treatment at the initial stages of tooth decay, is a priority for dentists. Timely intervention is necessary to prevent the progression of decay. In a study by Karimi et al. (2014), digital intraoral radiographic images were analyzed using MATLAB software, and histograms and their power spectra were calculated. Histogram analysis shows the distribution of data values and provides a visual overview of a specific frequency in the form of a bar chart. Based on the pixel intensity in various ranges, images are classified into different categories according to the severity of tooth decay. Figure 2 illustrates an X-ray image of a normal tooth along with its corresponding histogram.

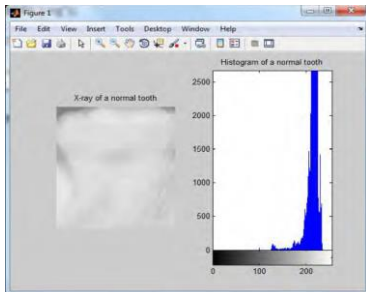


Figure 2. X-ray image of a normal tooth and its histogram (Karimi et al., 2014)

In the histogram of a normal tooth, the pixel intensity ranges from 200 to 250. In the early stages of tooth decay, the range is from 175 to 255, and in advanced stages of decay, it falls between 0 and 150. The analysis of the tooth spectrum reveals the frequency range of various components in a two-dimensional image. The power at each location in the spectrum represents the frequency and orientation of a specific image feature, making it an effective method for noise reduction in images. Figure 3 shows the X-ray image of a tooth along with its corresponding spectrum.

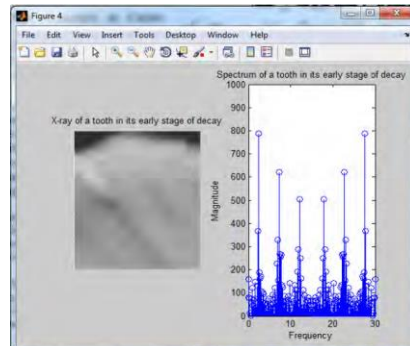


Figure 3. X-ray image of a normal tooth and its spectrum (Karimi et al., 2014)

In the spectrum of a normal tooth, the maximum amplitude value is less than 600. In the early stages of decay, the range is from 600 to 800, in the mid stages it ranges from 800 to 1000, and in the advanced stages of decay, the maximum amplitude value exceeds 1000. Various studies have shown that classifying different stages of decay based on pixel intensity, as well as spectrum amplitude values, is an effective and beneficial method for clinicians to diagnose early stages of tooth decay (Karimi et al., 2014).

Clinically, diagnosing occlusal lesions on the tooth surface is challenging due to its morphology, as the three-dimensional and complex structure of the occlusal surface varies significantly from one individual to another. This variation makes the diagnosis of decay difficult for dentists. Despite advanced techniques, the poor performance of radiographic images led experts to search for a better system. However, studies and solutions by Yomemuri et al. (2010), Kzit Bornchi et al. (2006), and Olsen et al. (2010) should not be overlooked.

In 2013, a non-invasive and automatic method for detecting decay areas was proposed (Kodeshori et al., 2013). In this method, decay was detected using only color camera images without the need for X-ray imaging or photography. The method consists of three stages: 1- Detection of decalcified areas (DA), 2- Detection of decay areas (OCA), and 3- Integration of the results of DA and OCA detection. The detection process is performed in parallel for DA and OCA areas, each of which involves four stages: preprocessing, region segmentation, feature extraction, and object removal.

The first indication of occlusal decay is the appearance of a white chalky spot on the tooth surface. As the lesion progresses, it turns light brown and eventually dark brown or black. Dark areas are displayed in red for dark brown areas, green for light brown areas, and blue for early stages of decay.

Finally, by combining the identified objects from DA and occlusal identified objects, the mass centers of the areas are calculated. Figure 4 shows the results of segmentation using the proposed method by Kodeshori et al. (2013) and manual segmentation.

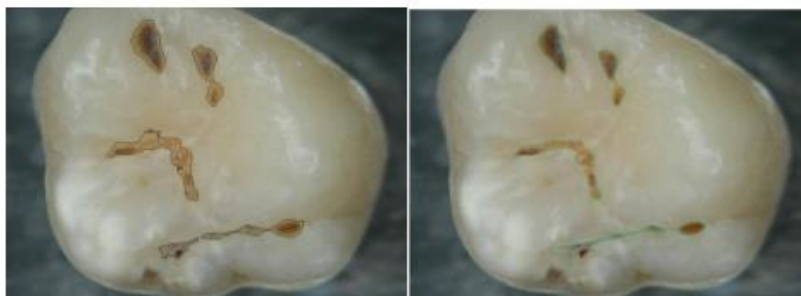

Figure 4. Final segmentation results (Left: Proposed method from Kodeshori et al., 2013, Right: Manual segmentation) (Kodeshori et al., 2013)

This method provided at least an 8% better performance compared to other proposed methods. The obtained sensitivity was 92%, and the accuracy was 80%, which are satisfactory and fruitful results (Kodeshori et al., 2013).

Bitewing images are commonly used to show interproximal tooth decay. These images include the crowns of the posterior teeth in both the upper and lower jaws, helping dentists determine appropriate crown size or other restorations. Digital bitewing radiography has widespread use in detecting proximal tooth decay (Rochkin Bozh, 2008). The separation of teeth in bitewing images using image processing can serve as a diagnostic aid for dentists. To this end, various methods for separating teeth have been proposed. In the study by Ahmadzadeh et al. (2014), a new method for separating teeth from the jaw and also separating the tooth crown from the root was presented. This method works by using horizontal projection histograms, where the total brightness intensity of each row of pixels is extracted and placed in a matrix. The value of each row of the matrix is converted to a signal. The minimum signal values are calculated using an adaptive window, and the middle pixels of each vertical line are determined. By connecting these points, the initial cutting location is drawn, which represents the horizontal curve and separator between the two jaws (Figure 5).

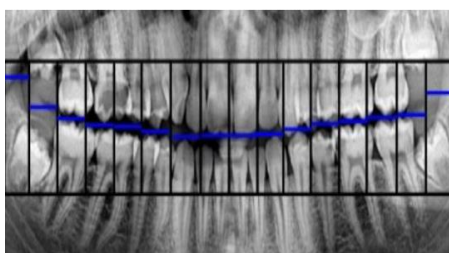


Figure 5. Creating the window and horizontal strip (Ahmadzadeh et al., 2014)

In the next step, using the sum accumulator, the rows of the image matrix are calculated. The horizontal separating line between the jaws is drawn by sliding the window with the horizontal center of gravity (Figure 6). Finally, by calculating the minimum vertical signal value in each window, the secondary cutting path is created. With this cut, the upper and lower jaws are completely separated from each other (Figure 7). To separate the teeth from one another, vertical projection is used (Figure 8).

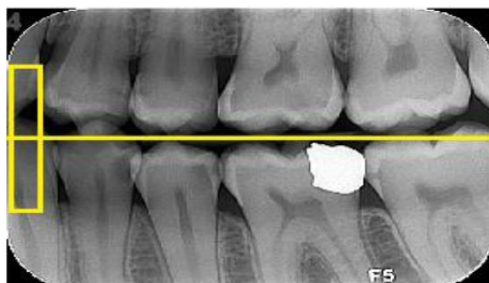

Figure 6. Initial Cutting Path of the Teeth and Sliding Window (Ahmadzadeh et al., 2014)

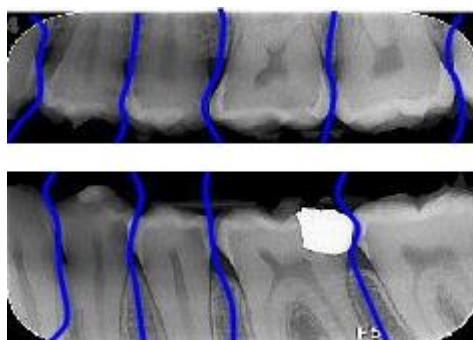


Figure 7. Secondary Cutting Path (Ahmadzadeh et al., 2014)

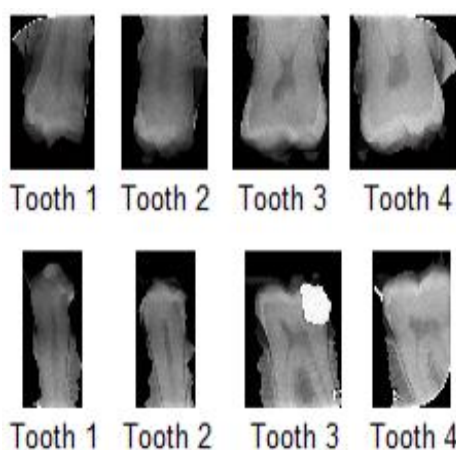


Figure 8. Separation of Teeth Using Secondary Cutting Path (Ahmadzadeh et al., 2014)

In the mentioned study, after separating the upper jaw from the lower jaw and extracting individual teeth, the center of the tooth is considered to be approximately one-third of the length and one-half of the width of the tooth. Pixel values are calculated using filtering and contrast enhancement, and by applying thresholding, the crown is separated from the root (Figure 9).

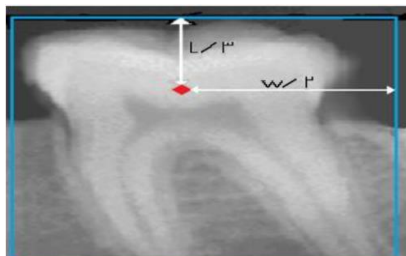

Figure 9. Extracted Single Tooth from Jaw (Ahmadzadeh et al., 2014)

The results obtained from applying this method on bitewing images show an improvement in quality compared to previous methods for separating the crown from the root (Ahmadzadeh et al., 2014).

4. Automatic Tooth Identity Recognition Based on Image

One of the applications of panoramic radiographs is the automatic identification of individuals using image analysis. However, one of the major challenges in automatic age estimation based on these radiographs is incorrect segmentation of the tooth images. To address the shortcomings of previous methods and to properly combine information from earlier works, the improvement of tooth segmentation for automatic tooth detection in panoramic radiographs has been explored in (Taghavi et al., 2014). In the modified segmentation, each tooth is separated from the others, and the boundary lines between the teeth are correctly identified. For the segmentation of panoramic radiographs, the border between the jaws is first revealed using probability density and the cumulative horizontal graph. The cumulative graph sums the pixel values in a specific row or column direction. In Figure 4, the boundary between the upper and lower jaws has been separated using this method.

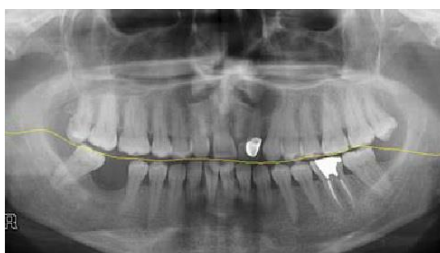

Figure 4. Continuous Boundary Between the Jaws (Taghavi et al., 2014)

In the next stage, the vertical cumulative graph for the upper and lower jaws is calculated separately. After noise removal using mean filtering and selecting boundary lines, the teeth are separated from each other. The boundary lines are placed between the two teeth, and the number of these lines should be equal to the number of teeth minus two (Figure 5).

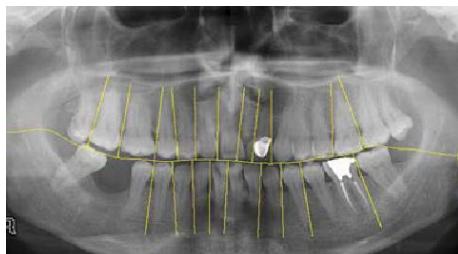


Figure 5. Final Segmentation Result (Taghavi et al., 2014)

Finally, using the evaluation of the studied images, an accuracy of 96.44% was achieved. This method is one of the first attempts on panoramic radiographs and is quite simple yet effective (Taghavi et al., 2014).

5. Temporal Evolution of Tooth Whitening During the Use of Mouthwash and Hydrogen Peroxide

Today, in addition to caring for and treating their teeth, individuals are increasingly concerned about the aesthetic appearance of their teeth. One of the cosmetic methods for whitening teeth is the use of hydrogen peroxide, which has provided satisfactory results for individuals (Goldstein, 1997). This substance is used as a disinfectant and for preventing plaque and gum inflammation in hygiene products such as gels, toothpaste, and mouthwash (Morris & Chapman, 2013). Continuous use of these products can lead to enamel wear, destruction of minerals, and increased tooth sensitivity (Glypton, 2014). In the article by Diaz et al. (2014), researchers presented a new method for determining the degree of tooth whitening and the extent of use of these materials. They conducted their experiments using a digital microscope, hydrogen peroxide, and tooth samples (Figure 12).

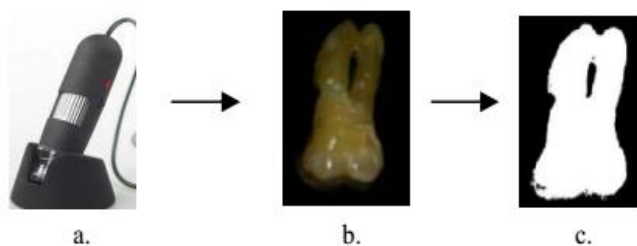


Figure 12. a) Digital Microscope, b) Tooth Image, c) Segmented Image (Diaz et al., 2014)

In this study, the tooth sample was immersed in 20 milliliters of 3.6% hydrogen peroxide and analyzed at intervals of 0, 24, 48, 144, and 240 hours. After each time period, a digital microscope image of the tooth was captured, processed, and analyzed. Finally, its histogram chart was calculated (Figure 13).

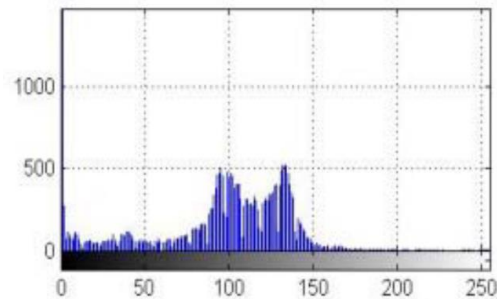


Figure 13. Histogram of Tooth Image

The results showed that the tooth immersed in the peroxide solution showed a significant increase in whitening between 96 hours and 240 hours, which led to a change in the histogram. This time frame also caused weakening of the tooth enamel. Additionally, the comparison of images revealed that teeth which used hydrogen peroxide whitener intermittently achieved satisfactory results. Therefore, this method allows for determining the amount of the substance used and the level of patient satisfaction in a way that minimizes side effects for the patients' teeth (Diaz et al., 2014).

6. Conclusion and Future Work

This article provided a brief overview of image processing techniques in the field of dentistry, addressing applications such as the detection of interproximal cavities without lesions, age and identity determination through panoramic radiography, crown-to-root separation, and the color changes in teeth during whitening treatments. Based on the promising results obtained from the reviewed studies, the importance and value of using image processing in dentistry and oral health are increasingly recognized. Therefore, the wide application of image processing in dentistry is emphasized, encouraging dentists to combine digital technologies with conventional methods. By employing modern, automated computer-based image processing techniques, more effective methods for diagnosing and treating oral diseases can be achieved. With the growing use of digital image processing and the innovations related to it in the field of dentistry, a brighter future for dentistry is expected.

7. References

- [1] Ahmadzadeh, Sh., Abbasi Dezfouli, M., & Abbasi Dezfouli, Th. (2014). "Tooth Crown Separation from Root Using Bitewing Radiographs via Image Processing," Proceedings of the Second National Conference on New Technologies in Electrical and Computer Engineering, Islamic Azad University, Fasa Branch, October 3, 2014.
- [2] Ardabili, Sandus & Qassabi, Amir Mehdi. (2024). "Methods of Creating Medical Images and Image Processing Techniques in Disease Diagnosis," 21st National Conference on Electrical Engineering, Computer Science, and Mechanics, Shirovan. <https://civilica.com/doc/1992258>
- [3] Stanley, J.T. (2014). "Anatomy and Morphology of the Tooth," Translated by Mustafa Moazami, Sara Tavakkolizadeh, Sara Majidinia, Elahe Mahmoodi Hashemi, Hila Haji Zadeh, Royan Pajouh, Tehran, 2014.



- [4] Amirkhosro, M., & Jafari, M. (2008). "Replacement of Conventional Radiography with Digital Radiography," Second International TINDT Technology Conference, Tehran.
- [5] Taghavi, M., Montazeri Kordi, H., Aghagolzadeh, A., & Abasi, F. (2014). "Improvement of Tooth Segmentation in Panoramic Radiographs Using Image Processing," Second Regional Conference on New Achievements in Electrical and Computer Engineering, November 18, 2014, Islamic Azad University, Jouybar Branch.
- [6] Robertson, T., Hyman, H., & Swift, E. (2006). "The Science and Art of Dentistry," Translated by Kamran Arastoo Poor, Volume 1, Shayan Noudar, Tehran, Summer 2008.
- [7] Reisi, Niloufar. (2024). "Application of Image Processing in Medicine (Tumor Diagnosis)," Second National Conference on Electrical and Biomedical Engineering Challenges and Solutions, Shiraz. <https://civilica.com/doc/1950558>
- [8] Zarei Akbatan, Elaheh & Shiri Ahmadi Abadi, Mohammad Ibrahim. (2024). "A Combined Method for Improving Brain Tumor Classification Diagnosis," First International Conference on Information Technology, Management, and Computer Science, Sari. <https://civilica.com/doc/2083751>
- [9] Shams Al-Ketabi, Shahram, Emami, Hamidreza, & Zarei Chavoshi, Samira. (2017). "Heart Disease Detection Using PCA and Neural Networks," Third National Conference on Electrical and Computer Engineering, Amin University, Isfahan. <https://civilica.com/doc/642345>
- [10] Safdarian, Nasser & Jafar Neia Dabanlu, Nader. (2021). "COVID-19 Diagnosis Using CT Scan Image Processing Techniques," Journal of Health Informatics and Biomedical Sciences, Volume 8, Issue 1. <https://civilica.com/doc/2036424>
- [11] Azizi, Rezvaneh & Abbasi Nishabouri, Hamid. (2024). "Exploring the Application of Deep Convolutional Neural Networks in CT Scan Image Processing for COVID-19 Diagnosis," Third International Conference on New Achievements in Information Technology, Computer Science, Security, Networks, and Artificial Intelligence, Mashhad. <https://civilica.com/doc/2057095>
- [12] Karimi Mirdani, M., Qahari, Sh., & Gholami, F. (2014). "Early Detection of Tooth Decay Using Histogram Analysis and Power Spectrum," First National Electrical Engineering Conference, Islamic Azad University, Langeroud Branch.
- [13] Ghodrati, Reza & Bagheri, Gita. (2017). "Using Optimization Algorithms and Comparing Them in Leukemia Cancer Diagnosis with Neural Networks," International Conference on Engineering and Information Technology, <https://civilica.com/doc/631641>
- [14] Moeini, Fatemeh, Chale Chale, Abdollah & Safri, Faizeh. (2024). "A Review of Disease Diagnosis Methods in Dentistry Using Image Processing and Deep Learning Techniques," First International Conference on Information Technology, Management, and Computer Science, Sari. <https://civilica.com/doc/2084000>
- [15] White Faro, E. (2014). "Fundamentals of Oral Radiology," Translated by Ahmadreza Talayipour, Sandra Mehrazadeh, Shirin Sekhdari, Ladan Hafezi, Azadeh Baqeri, Yaser Safai, Pegah Boronoush, Shayan Noudar, Spring 2015.
- [16] Houde Shanas, Armaghan, & Attarzadeh, Iman & Haroon Abadi, Ali. (2024). "An Efficient Method for Improving the Accuracy of Brain Tumor Diagnosis Based on Image Processing Techniques and Machine Learning," Tenth International Conference on Interdisciplinary Research in Electrical, Computer, Mechanical, and Mechatronics Engineering in Iran and the Islamic World, Tehran. <https://civilica.com/doc/2110522>



- [17] Hilton, T., Ferrakan, J., & Broom, J. (2013). "Principles of Restorative Dentistry," Summit 2013, Translated by Azam Valian, Elham Marjaf Saleh, Anahita Pourhashemi, Bahar Javid, Faizeh Jamali, Niloufar Kianvash Rad, Afrooz Nokhostin, Hanieh Norouzi, Royan Pajouh, Tehran, 2014.
- [18] Yasini, E., Ahmadi Zanoor, Gh., Akbari, M., Amiri, M., Eskoei, S., Amin Salehi, E., & Banoua, S. (2016). "National Restorative Dentistry Book," Jihad Daneshgahi, Tehran, Spring 2017.
- [19] Clifton, M. (2014), "Tooth Whitening: What We Now Know," The Journal of Evidence-Based Dental Practice, pp 1-19.
- [20] Díaz, L., Morales, Y., & Torres, C. (2014, September), "Study of the temporal evolution of whitening in teeth undergoing mouthwashes using digital image processing," In *Image, Signal Processing and Artificial Vision (STSIVA), 2014 XIX Symposium on* (pp. 1-4). IEEE.
- [21] Goldstein, RE. (1997), "The In-office bleaching: where we came today", 128, pp 5-11.
- [22] <http://www.wisegeek.org/what-is-tooth-decalcification.html>.
- [23] <http://article.tebyan.net>.
- [24] <http://daneshnameh.roshd.ir/mavara/mavara-index.php>.
- [25] <http://drbassirradiology.ir>.
- [26] <http://elecpro.ir>.
- [27] <http://www.dandane.ir>.
- [28] <http://www.drhashemi.ir/dentistry/17-teeth.html>.
- [29] <http://www.iranianbme.com>.
- [30] <http://www.winghavenortho.com/decalcification.php>.
- [31] Kositbowornchai, S. and Siriteptawee, S. and Plermkamon. S. and Bureerat, S. and Chetchotsak, D. (2006), "An artificial neural network for detection of simulated dental caries," Int J CARS, pp 91-96.
- [32] Koutsouri, G. D., Berdouses, E., Tripoliti, E. E., Oulis, C., & Fotiadis, D. I. (2013, November), "Detection of occlusal caries based on digital image processing", In *Bioinformatics and Bioengineering (BIBE) Confronce*.
- [33] Morris and Chapman (2013), "Blanqueadores Dentales y Productos de Higiene Bucal con Peroxido de Hidrogeno," GreenFacts Facts on Health and the Environment, Edition, Prentice-Hall, Inc.
- [34] Mousavinasab, M. and Ashrafi-joo, S. (2004), "An In-vitro Evaluation of Effects of Light-Heat Curing Inlay Composite Rstorations on Fracture Resistance of Pulpless Maxillary Premolars," Journal of Dentistry of Tehran University of Medical Sciences, 1, pp 32-37.
- [35] Olsen, G. (2010), "Fundamental work toward an image processing-empowered dental intelligent education system," PhD thesis, Virginia Commonwealth University.
- [36] Rockenbach, m. (2008), "Detection of proximal caries in conventional and digital radiographs:an in vitro study," Baltic Dental and Maxillofacial Journal, 17, pp: 115-127.
- [37] Strassler, E. (2002), "New Concept in Caries Detection of Pit and Fissions", Howard University of Maryland Dental School.
- [38] Umemori, S. and Tonami, K. and Nitta, H, and Mataki, S. and Araki, K. (2010), "The Possibility of Digital Imaging in the Diagnosis of Occlusal Caries," International Journal of Dentistry.